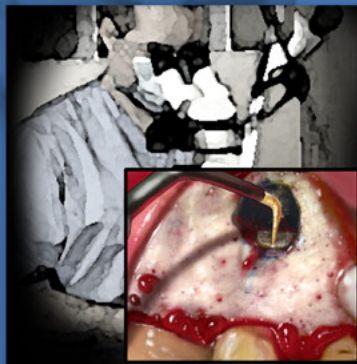


ENDODONTICS

*Colleagues for
Excellence*



Fall 2010

*Contemporary Endodontic Microsurgery:
Procedural Advancements and Treatment
Planning Considerations*



Published for the Dental Professional Community by the
American Association of Endodontists

Why do we Need Endodontic Microsurgery?

Nonsurgical endodontic treatment, or root canal treatment, achieves a high rate of clinical success despite the anatomic and pathologic challenges of the procedure. Success in cases without periapical extension of pathosis is better than 90%, while studies show that infected root canals with an extension of pathosis into the periapical space have a decreased degree of healing.¹ A nonhealing endodontic lesion is recognized by persistent pain and/or swelling, possibly with radiographic changes indicating increasing periapical bone loss. Inflammation of the periapical tissue (symptomatic apical periodontitis) is the source of this persistent pain, and given enough time, can also manifest with radiographic evidence of an enlarged ligament space or the formation of an apical osseous lesion from the resulting bone loss and swelling of the soft tissues. Instances of endodontically treated teeth that do not appear to be healing are not automatic indications for extraction and replacement with an implant. In many of these cases, a tooth may be scheduled to undergo nonsurgical retreatment with the aim of further disinfecting the root canal space to permit healing of the apical periodontitis. In instances where nonsurgical retreatment cannot solve the problem a significant number of persistent nonhealing cases can be saved by endodontic microsurgery with a predictably favorable prognosis.

Endodontic microsurgery (apicoectomy) in its broadest sense is the treatment performed on the root apices of an infected tooth, followed by placement of a filling (retrofilling) to seal the root end. In the past, this surgical procedure was performed by endodontists, oral surgeons and general practitioners using the then-traditional techniques of preparing the canal space with a round bur attached to a straight handpiece and using amalgam as the root-end filling material. Advances over the past decades, supported by ongoing research, have led to a refinement of these techniques, materials and instruments. These advancements are centered on the use of the surgical operating microscope to provide unsurpassed magnification and illumination for all phases of the treatment process.

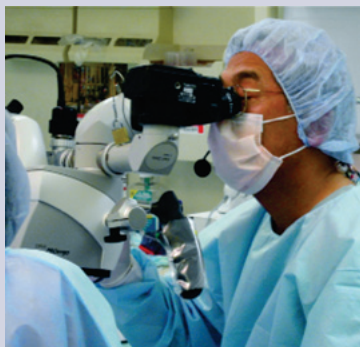

Fig. 1. An endodontist performing microsurgery using an operating microscope.

As a result, the procedures have changed in ways that significantly affect the success, the overall case selection, the application for this now-predictable procedure, as well as the postoperative healing sequelae. Today's apical surgery is more correctly termed endodontic microsurgery, due to the significant aid of the surgical operating microscope, shown in Figure 1, which is fundamentally and significantly different from the traditional technique.² Studies looking at the success of traditional apical surgery, outlined in Table 1, indicate that it is almost fifty percent less successful than current microsurgical success data.^{3,4,5,6,7,8,9,10,11,12,13,14}

The microsurgical materials and instruments that define the technique of apical surgery as performed by endodontists are the main reasons for this elevated success and enhanced ability to retain teeth otherwise slated for extraction. The microscope enables accurate visualization, identification and treatment of infected extraradicular canals, isthmuses and irregular anatomy unreachable with traditional instrumentation techniques.

Anatomic studies over the years, using various methods of evaluation, consistently reveal the complex anatomy that must be addressed when the root canal space becomes infected and must be cleaned and shaped.^{15,16} Research continues into improvements in instrument design and irrigation techniques that will enable the dentist to more completely clean and shape these complexities.¹⁷ There are instances, however, where endodontic microsurgery offers clear advantages over orthograde endodontics and can increase success rates.

Root dentin is composed of dentinal tubules that bacteria are known to penetrate; sometimes through the entire thickness of the root to the cementodentinal junction.¹⁸ This penetrating bacterial load poses a potential etiology for the apical pathosis seen in the nonhealing of some orthograde endodontic cases. The root canal's apical anatomy can be even more challenging to access and clean due to multiple portals of exit that can leave the root at sharp angles with small radii of curvature. In situations like these, stainless steel or nickel-titanium files may not be able to negotiate these areas without a risk of file separation, therefore inhibiting proper cleaning and disinfection of the root canal space.¹⁶ In addition, apical resorption may alter apical anatomy making the root end more difficult to effectively treat nonsurgically.^{18,19}

Surgical Advances in the Last Decade and Their Positive Effects on Outcome

Several specific changes in the microsurgical approach are proven to increase the procedure's success. These include:

1. A smaller osteotomy, approximately 3-4mm in diameter (Figure 2)
2. Root-tip resection of 3mm to eliminate lateral canals and apical ramifications

Table 1

Microsurgery						
Author/Year	Sample size	Follow-up (yrs)	Magnification	Root-end Preparation	Root end Filling	Success
Christiansen et al (2009)	22T	1	Microscope	Ultrasonic	MTA	96%
Taschieri et al (2008)	100 (59/41)	2	Endo vs Micro	Ultrasonic	EBA	90%-92%
Kim et al (2008)	192 T	2	Microscope	Ultrasonic	IRM/EBA/MTA	95.2%
Taschieri et al (2007)	30 T	1	Endoscope	Ultrasonic	EBA	93%
Tsesis et al (2006)	45 T	1 to 4	Microscope	Ultrasonic	IRM	91.1%
Chong et al	108 T	1 to 2	Microscope	Ultrasonic	IRM/MTA	87%-92%
Rubinstein and Kim (2002)	59 R	5 to 7	Microscope	Ultrasonic	EBA	91.50%
Rubinstein and Kim (1999)	91 R	1	Microscope	Ultrasonic	EBA	96.80%
Traditional Surgery						
Author/Year	Sample size	Follow-up (yrs)	Magnification	Root-end Preparation	Root end Filling	Success
Tsesis et al (2006)	43 T	1 to 4	None	Bur	IRM	44.2%
Arad et al (2003)	122	11.2 mean	None	Bur	Amalgam/IRM	44.3%
Wessen and Gale (2003)	1007	5	None	Bur	Amalgam	57%
Rahbraran et al (2001)	176	1	None	Bur	Amalgam/IRM/No fill	19.4%
Haise et al (1991)	474	1	None	Bur	Amalgam	68.7%

3. A decreased or no root resection bevel angle (Figure 2)
4. Clear inspection of the resected root surfaces to visualize fractures, isthmuses or other anatomical complexities (Figure 3)
5. 3mm depth preparation of the long axis of the canal
6. Root-end fillings with MTA (Mineral Trioxide Aggregate), an osteo- and cemento-inductive material (Figure 4, see p. 4)

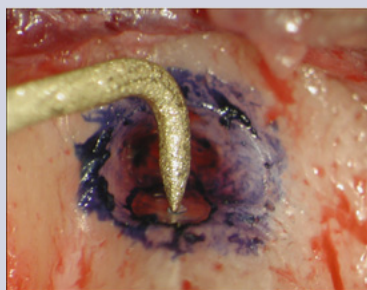

Fig. 2. An ultrasonic tip (Kis tip #1) in action: a 4mm diameter osteotomy and 3mm tip length.

The ability to work within a smaller osteotomy involving reduced bone removal permits quicker healing and results in less eventful postoperative healing.³ By removing less bone, especially in the coronal direction, the buccal plate can be preserved and subsequent periodontal sequelae that

may otherwise lead to the loss of the tooth are prevented.²⁰ The use of the operating microscope and specially designed instruments enhance access to more challenging locations, such as access to very narrow spaces, by providing a clear field of vision. Better visualization also prevents damage to strategic anatomical structures, such as the mental nerve and maxillary sinus. Microscopic techniques significantly decrease complications and expand the case applicability for performing this procedure on teeth adjacent to these

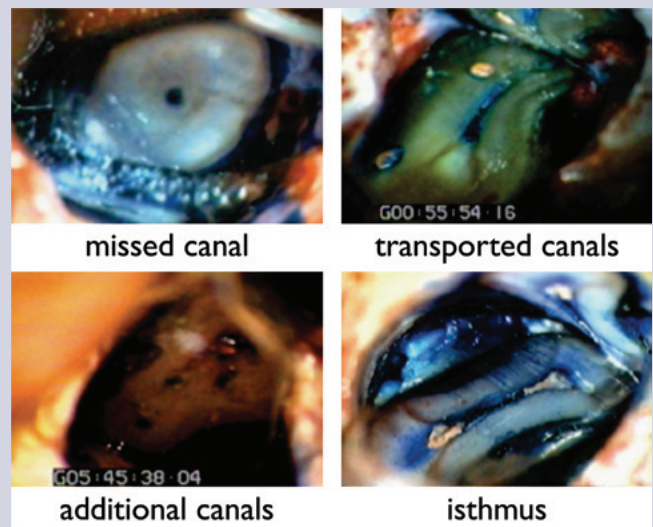


Fig. 3. Resected root surfaces demonstrating numerous variations of anatomy. In roots resected 3mm apically, there are four representations demonstrated with Methylene Blue Stain. The portal of exit can be identified in totally calcified canals (upper left); transported canals leaving the isthmus intact (upper right); more than one portal of exit (lower left); and uncleaned isthmus (lower right). These pictures demonstrate that root-end filling should be placed after the apicoectomy.

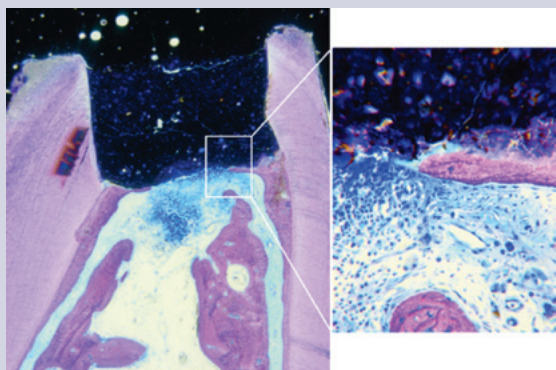


Fig. 4. Photo-micrographs of the effects of MTA used as a perforation repair material on cementum in dog teeth. Notice the regeneration of cementum beneath the MTA that stimulates hard tissue formation resulting in healing.

structures. With increased magnification and illumination, differentiating the root surface from the surrounding bone is also enhanced.

A main cause of nonsurgical endodontic failure results from the inability to clean and sterilize the apical canal space, which is a complex anatomical entity. A study shows that the resection of 3mm of apex eliminates 98 percent of apical ramifications and 93 percent of lateral canals.²

More effective microsurgical root-end preparations have been made possible by specially designed ultrasonic tips that permit accurate preparation along the long axis of the root canal without blocking visibility during preparation. This technique permits the placement of root-end fillings in the proper position to seal the root canal as well as a sufficient filling depth (3mm) or thickness to effectively seal the canal, dentinal tubules and accessory canals that may be present.²¹

A minimum of 3mm preparation depth is needed to prevent leakage, therefore the ideal ultrasonic tip length is 3mm long, such as the KiS tip illustrated in Figure 2. Among the many widely used filling materials, such as SuperEBA and IRM, research has shown that MTA is a superior material for endodontic microsurgery due to its excellent biocompatibility, osteo- and cemento-inductive capabilities, effective antibacterial and sealing properties, and faster radiographic healing.^{22, 23, 24, 25} This is illustrated in Figure 4. MTA also does not have the disadvantage of causing soft tissue discoloration (tattoos) that can result from root-end filling materials like amalgam. These advances permit not only the effective surgical retreatment of teeth but also the revision of surgical cases that were previously treated by apical surgery using traditional techniques and amalgam root-end fillings. The comparison of traditional apical surgery and endodontic microsurgery is shown in Table 2.

Endodontic microsurgery represents a minimally invasive treatment option by allowing the retention of the existing intact coronal restoration, as well as maintaining the gingival and periodontal structures from a functional as well as aesthetic aspect, when compared to nonsurgical retreatment or complete extraction and implant placement. Submarginal flap designs, using microscopic instruments and precise tissue handling with microsuturing, permits the delicate manipulation of tissues. This in turn permits proper access while preserving the hard and soft tissue architecture and facilitates reapproximation and healing without scarring, thereby eliminating potential aesthetic problems.

Table 2

	Traditional Apicoectomy	Endodontic Microsurgery
Magnification	Eyes or Loupes (1-4x)	Microscope (4-24x)
Illumination	Dental light	Bright focused light
Armamentarium	Macro-instruments	Micro-instruments
Osteotomy Size	Large (7-10mm diameter)	Small (3-3mm diameter)
Bevel Angle	Acute (45-60 degree)	Shallow (0-10 degree)
Root-end Preparation	Non-axial	Axial to long axis of tooth
Depth of Root-end prep	1mm non-axial	3mm axial
Inspection resected root surface	None	Always
Root-end filling material	Amalgam	MTA
Success rate over 1 year	Less than 50%	Over 90%

Indications for Endodontic Microsurgery

Indications for microsurgery when nonsurgical endodontics has been unsuccessful are clear in many situations. For instance:

1. Adequately executed endodontics but failed with a persistent periapical radiolucent lesion (Figure 5A)²⁶
2. Adequately executed endodontics with constant pain with or without swelling
3. Apical transportation, ledges and other iatrogenic problems with persistent pathology and symptoms (Figure 5C)
4. Tooth with a large post and crown restoration completed, especially maxillary anterior teeth (Figures 5B and 5D)
5. Calcified canals with or without symptoms and PAR (periapical radiolucency) (Figure 5D)
6. Broken instrument in apical half of the root (Figure 5E)
7. Failed traditional surgery (Figure 5F)
8. Overfilled canal with PAR (Figure 5G)
9. Complex/compound apical curvatures that are inaccessible from an orthograde approach

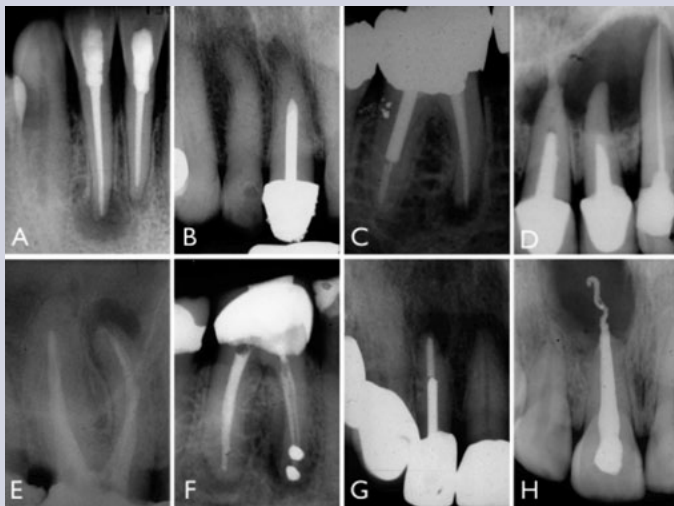

Fig. 5. Some selected cases requiring microsurgery: **A.** Persisting PAR despite adequate endodontic treatment, **B.** Calcification, **C.** Apical transportation of the mesial root, **D.** Large post without endodontics and a large PAR in anterior teeth, **E.** Broken file at apical one-third and PAR, **F.** Failed traditional technique apical surgery, **G.** Excellent endodontic treatment with post but persistent PAR in maxillary anterior, **H.** Overfilled root canal with large persisting PAR.

In approximately 20 percent of cases that involve periapical lesions, nonsurgical endodontic treatment may simply not work due to the cystic nature of the lesions.^{27,28,29} Such lesions must be treated by surgical intervention, although some advocate that cystic lesions could heal by nonsurgical treatment.³⁰ Evidence suggests that there is an approximate reduction of 20 percent success when a PAR is present compared with cases without a PAR. This difference may possibly be due to the cystic nature of the lesion.

In cases of iatrogenic canal blockage where instrument separation occurs, endodontic microsurgery additionally provides a nondestructive and successful means to address instrument separation that may occur during the cleaning and shaping phase of nonsurgical endodontics. In cases of instrument separation where the fragments are in the apical third of curved roots and cannot be removed, a microsurgical approach is a safer and predictable means to manage these cases.³¹⁻

³² Attempting instrument removal nonsurgically can

result in removal of critical supportive root dentin resulting in a higher risk for developing a vertical root fracture. Studies clearly indicate that vertical root fractures are irreparable situations, so increasing a tooth's chance of fracture by attempting instrument retrieval nonsurgically can decrease its prognosis. The surgical approach affords the benefit of maintaining the root's strength while being able to safely retrieve a separated instrument and effectively seal the infected canal.

Endodontic microsurgery provides a treatment option for canal calcification or severe curvature due to its direct access to the root end. In cases of overfilling, endodontic microsurgery is an effective and safe means to remove extruded root-filling materials and infected debris that can cause periapical inflammation.

Where Can Endodontic Microsurgery Fit Into the Treatment Plan for a Patient?

Endodontic microsurgery should not be viewed as the last resort. It should be an integral part of endodontic retreatment regimens.² As such, we should use it where indicated to save the form and function of the natural teeth. It is a predictable method that effectively eradicates the causes of persistent apical pathosis with little postoperative discomfort.^{33,34} When a tooth has been previously treated by root canal treatment, but still has persisting symptoms and the patient wants to save the tooth, retreatment of the root canal should be considered. There are two potential means—nonsurgical by accessing through the crown or surgically by directly accessing the root apices and periapical pathosis.

Both procedures are very effective and supporting research shows that these procedures will result in the healing of apical periodontitis in an average of 80 percent of the cases treated, meaning symptoms resolve and apical bone is reformed permitting retention of the tooth.³⁵

The decision to retreat a case surgically or nonsurgically can be a challenge and should be based on individual circumstances. Current research has shown that when the initial root canal treatment appears to be performed in an adequate fashion, the success of a nonsurgical retreatment is significantly decreased, suggesting that apical surgery may be the preferred option.²⁶ As shown in the previous section on indications for endodontic microsurgery, clinicians must advise patients that the microsurgical approach is a treatment option that is preferred to nonsurgical retreatment, extraction or implant placement. Implants are a marvel of modern-day dentistry where indicated, but abuse of this technique can be catastrophic for patients.

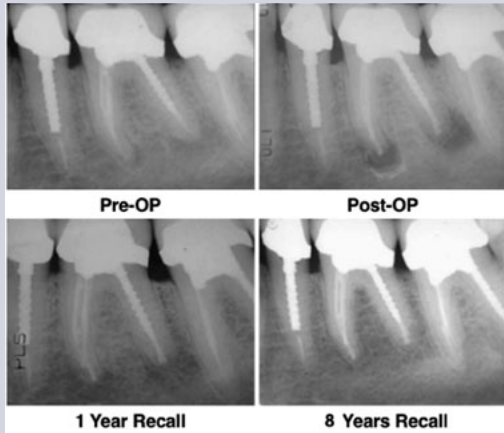

Fig. 6. An 8-year recall of #19 treated by microsurgery. Notice the complete resolution of the PAR and total regeneration of the periapical tissues.

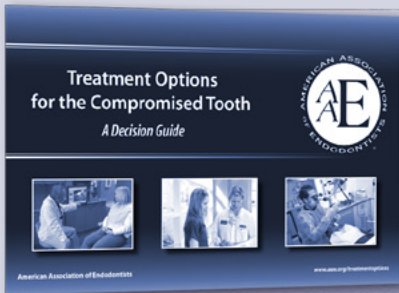
Summary

There are many factors to consider when choosing to perform microsurgery on a tooth versus performing other treatment options such as nonsurgical retreatment or tooth extraction. Fortunately for the patient, the ability to perform endodontic microsurgery is an effective and highly successful procedure that produces minimal discomfort, alleviates periradicular pathosis, maintains restorations and provides for function and aesthetics as shown in Figure 6.^{33,34}


References

1. de Chevigny C, Dao T, Basrani B, Marquis V, Farzaneh M, Abitbol S, Friedman S. Treatment Outcome in Endodontics: The Toronto Study—Phase 4: Initial Treatment. *J Endodon* 2008;34:258-63.
2. Kim S, Kratchman S. Modern Endodontic Surgery Concepts and Practice: A Review. *J Endodon* 2006;32:601-23.
3. Rubinstein R, Kim S. Short-term observation of the results of endodontic surgery with the use of a surgical operation microscope and Super-EBA as root-end filling material. *J Endodon* 1999;25:43-8.
4. Christiansen R, Kirkevang LL, Hørsted-Bindslev P, Wenzel A. Randomized clinical trial of root-end resection followed by root-end filling with mineral trioxide aggregate or smoothing of the orthograde gutta-percha root filling—1-year follow-up. *Int Endod J* 2009;42:105-14.
5. Taschieri S, Del Fabbro M, Testori T, Weinstein R. Microscope versus endoscope in root-end management: a randomized controlled study. *Int J Oral Maxillofac Surg* 2008;37:1022-6.
6. Taschieri S, Del Fabbro M, Testori T, Weinstein R. Endoscopic periradicular surgery: a prospective clinical study. *Br J Oral Maxillofac Surg* 2007;45:242-4.
7. Kim E, Song JS, Jung IY, Lee SJ, Kim S. Prospective clinical study evaluating endodontic microsurgery outcomes for cases with lesions of endodontic origin compared with cases with lesions of combined periodontal-endodontic origin. *J Endodon* 2008;34:546-51.
8. Tsesis I, Rosen E, Schwartz-Arad D, Fuss Z. Retrospective evaluation of surgical endodontic treatment: traditional versus modern technique. *J Endodon* 2006;32:412-6.
9. Chong BS, Pitt Ford TR, Hudson, MB. A prospective clinical study of Mineral Trioxide Aggregate and IRM when used as root-end filling materials in endodontic surgery. *Int Endod J* 2003;36:520-6.

10. Rubinstein RA, Kim S. Long-term follow-up of cases considered healed 1 year after apical microsurgery. *J Endodon* 2002;28:378-83.
11. Wesson CM, Gale TM. Molar apicoectomy with amalgam root-end filling: results of a prospective study in two district general hospitals. *Br Dent J* 2003; 195:707-14.
12. Rahbaran S, Gilthorpe MS, Harrison SD, Gulabivala K. Comparison of clinical outcome of periapical surgery in endodontics and oral surgery units of a teaching dental hospital: a retrospective study. *Oral Surg Oral Med Oral Pathol* 2001;91:700-9.
13. Halse A, Molven O, Grung B. Follow-up after periapical surgery: the value of the one-year control. *Endod Dent Traumatol* 1991;7:246-50.
14. Schwartz-Arad D, Yarom N, Lustig JP, Kaffe I. A retrospective radiographic study of root-end surgery with amalgam and intermediate restorative material. *Oral Surg Oral Med Oral Pathol Oral Radio Endod* 2003;96:472-7.
15. Weng X, Yu S, Zhao S, Wang H, Mu T, Tang R, Zhou X. Root Canal Morphology of Permanent Maxillary Teeth in the Han Nationality in Chinese Guanzhong Area: A New Modified Root Canal Staining Technique. *J Endodon* 2009;35:651-56.
16. Baugh D, Wallace J. The role of apical instrumentation in root canal treatment: a review of the literature. *J Endodon* 2005;31:333-40.
17. Peters OA. Current Challenges and Concepts in the Preparation of Root Canal Systems: A Review. *J Endodon* 2004;30:559-67.
18. Wu M-K, Wesselink P, Walton R. Apical terminus location of root canal treatment procedures. *Oral Surg Oral Med Oral Pathol Oral Radiol Endod* 2000;89:99-103.
19. Ricucci D. Apical limit of root canal instrumentation and obturation, part 1. Literature review. *Int Endod J* 1998;31:384-93.
20. Dietrich T, Zunker P, Dietrich D, Bernimoulin J-P. Apicomarginal defects in periradicular surgery: Classification and diagnostic aspects. *Oral Surg Oral Med Oral Pathol Oral Radiol Endod* 2002;94:233-9.
21. Gilheany P, Figdor D, Tyas M. Apical Dentin Permeability and Microleakage Associated with Root End Resection and Retrograde Filling. *J Endodon* 1994;20:22-6.
22. Saunders J. A prospective clinical study of periapical surgery using Mineral Trioxide Aggregate as a root end filling. *J. Endod* 2008;34:660-5.
23. Baek, SH, Plenk Jr H, Kim S. Periapical tissue responses and cementum regeneration with amalgam, super-EBA and MTA as root-end filling materials. *J Endodon* 2005;31:444-9.
24. Fernandez-Yanez S, Leco-Berrocal M, Martinez-Gonzalez J. Meta analysis of filler materials in periapical surgery. *Med Oral Patol Oral Cir Bucal* 2008;13:180-5.
25. Lindeboom J, Frenken W, Kroon F, van den Akker H. A Comparative Prospective Randomized Clinical Study of MTA and IRM as Root-End Filling Materials in Single-Rooted Teeth in Endodontic Surgery. *Oral Surg Oral Med Oral Pathol Oral Radio Endod* 2005;100:495–500.
26. de Chevigny C, Dao T, Basrani B, Marquis V, Farzaneh M, Abitbol S, Friedman S. Treatment Outcome in Endodontics: The Toronto Study - Phases 3 and 4: Orthograde Retreatment. *J Endodon* 2008;34:131-7.
27. Nair PN. Pathogenesis of apical periodontitis and the causes of endodontic failures. *Crit Rev Oral Biol Med* 2004;15:348-81.
28. Nair PN. New perspectives on radicular cysts; do they heal? *Int Endod J* 1998;31:155-60.
29. Simon JH. Incidence of periapical cysts in relation to the root canal. *J Endodon* 1980;6:845-8.
30. Lin L, Ricucci D, Lin J, Rosenberg P. Nonsurgical root canal therapy of large cyst-like inflammatory periapical lesions and inflammatory apical cysts. *J Endodon* 2009;35:607-15.
31. Ruddle C. Nonsurgical Retreatment. *J Endodon* 2004;30:827-45.
32. Parashos P, Messer H. Rotary NiTi Instrument Fracture and its Consequences. *J Endodon* 2006;32:1031-43.
33. Iqbal M, Kratchman S, Guess G, Karabucak K, Kim S. Microscopic Periradicular Surgery: Perioperative Predictors for Postoperative Clinical Outcomes and Quality of Life Assessment. *J Endodon* 2007;33:239-44.
34. Penarrocha M, Barcia B, Mart E, Balaguer J. Pain and inflammation after periapical surgery in 60 patients. *J Oral Maxillofac Surg* 2006;64:429-33.
35. Torabinejad M, Corr R, Handysides R, Shabahang S. Outcomes of Nonsurgical Retreatment and Endodontic Surgery: A Systematic Review. *J Endodon* 2009;35:930-7.



Saving the Natural Tooth *Just Got Easier*



Tough cases don't have to mean extracted teeth—many endodontic treatments can save the natural tooth for a lifetime! Our handy **Treatment Options for the Compromised Tooth Guide** helps you evaluate a variety of conditions using:

- case examples with radiographs and clinical photographs;
- clinical considerations;
- guidance for successful outcomes based on prognosis.

Also available—**Treatment Options for the Diseased Tooth** patient brochure!

- Describes endodontic treatment options in easy-to-understand language
- Explains the benefits of implants when a tooth must be extracted

Download your free copies today at www.aae.org/treatmentoptions!

The AAE wishes to thank Drs. Syngcuk Kim, Samuel Kratchman and Garrett Guess for authoring this issue of the newsletter, as well as the following article reviewers: Drs. James A. Abbott, William T. Johnson, Matthew V. Lindemann, Clara M. Spatafore and Susan L. Wolcott.

AAE COLLEAGUES ONLINE

Exclusive Bonus Materials

This issue of the *ENDODONTICS: Colleagues for Excellence* newsletter is available online at www.aae.org/colleagues with the following **exclusive bonus materials**:

- Full-Text Article: Barone C, Dao TT, Basrani BB, Wang N, Friedman S. Treatment Outcomes in Endodontics: The Toronto Study — Phases 3, 4 and 5: Apical Surgery. *J Endodon* 2010;36:28-35.
- Full-Text Article: Kim S, Kratchman S. Modern Endodontic Surgery Concepts and Practice: A Review. *J Endodon* 2006;32:601-23.
- Full-Text Article: Torabinejad M, Corr R, Handysides R, Shabahang S. Outcomes of Nonsurgical Retreatment and Endodontic Surgery: A Systematic Review. *J Endodon* 2009;35:930-7.
- Full-Text Article: von Arx T, Penarrocha M, Jensen S. Prognostic Factors in Apical Surgery with Root-end Filling: A Meta-analysis. *J Endodon* 2010;36:957-73.

All back issues of this newsletter are also available for your ongoing reference online.

Earn CE Online

Earn CE credit for the *ENDODONTICS: Colleagues for Excellence* newsletter series via the AAE Live Learning Center at www.aae.org/livelearningcenter.



The information in this newsletter is designed to aid dentists. Practitioners must use their best professional judgment, taking into account the needs of each individual patient when making diagnosis/treatment plans. The AAE neither expressly nor implicitly warrants against any negative results associated with the application of this information. If you would like more information, consult your endodontic colleague or contact the AAE.

American Association of Endodontists
211 E. Chicago Ave., Suite 1100
Chicago, IL 60611-2691
info@aae.org • www.aae.org

Did you enjoy this issue of *ENDODONTICS*? Are there topics you would like *ENDODONTICS* to cover in the future? We want to hear from you! Send your comments and questions to the American Association of Endodontists at the address at left.